

A Unusual Case of Painless Obstructive Jaundice and Cholangitis: Lemmel's Syndrome- A Case Report

Praveen S Padasali*, Vinayak Thakkannavar

ABSTRACT

A unusual case of periampullary duodenal diverticulum causing obstructive jaundice. Duodenal diverticula are detected in up to 27% of patients undergoing upper gastrointestinal endoscopy with periampullary diverticula (PAD) being the most common type. Although periampullary diverticula rarely cause obstructive jaundice when choledocholithiasis or tumor is not present. The periampullary duodenal diverticulum causing extrinsic compression of common bile duct and obstructive jaundice is called Lemmel's syndrome. An 58-yr-old woman came to the emergency room with obstructive jaundice and cholangitis. Abdominal CT scan revealed PAD compressing distal CBD with CBD dilatation. PAD shows signs of inflammation in CT scan and Endoscopy. Recognition of this condition is important since misdiagnosis could lead to mismanagement and therapeutic delay. Whenever PAD is present it should always be included as one of the differential diagnosis of obstructive jaundice.

Key words: Periampullary, Duodenal diverticulum, Obstructive jaundice, Cholangitis, Lemmel's syndrome.

INTRODUCTION

Lemmel's syndrome is obstructive jaundice caused by a periampullary duodenal diverticula causing extrinsic compression of CBD.^[1] Periampullary diverticula (PAD) refer to extraluminal outpouchings of duodenal mucosa that develop within the radius of 2 to 3 cm from the ampulla of Vater.^[2] PAD are largely asymptomatic but they sometimes can cause both pancreaticobiliary and non-pancreaticobiliary complications. Recently, we experienced an unusual case of painless obstructive jaundice and cholangitis due to extrinsic compression of distal common bile duct (CBD) by inflamed PAD. Herein, we report a case Lemmel's syndrome that was successfully managed conservatively.

Case description

An 58-yr-old woman presented to the emergency department with fever with chills (38.4°C) and yellowish discoloration of sclera since 8 days duration. She had no history of previous surgeries or similar complaints. On physical examination, patient was febrile with icterus present. There was no abdominal tenderness or mass felt on palpation. Her white blood count was increased to 18,200/ μ L (neutrophil 83.0%) and CRP was elevated to 2.42 mg/dL. The results of her liver function test were as follows: total bilirubin, 5.2 mg/dL; aspartate aminotransferase, 88 IU/L; alanine aminotransferase, 96 IU/L; alkaline phosphatase, 542 IU/L; and γ -glutamyl transpeptidase, 671 IU/L. To evaluate the cause of yellowish discoloration of sclera and fever with liver enzyme elevation in a cholestatic pattern, abdominal CT scan

was taken. The images of the CT scan demonstrated bile duct dilatation with no organic cause. However, on MRCP reconstructed images, there was PAD compressing the distal bile duct and signs of diverticulum (Figure 1) (Figure 2) (Figure 3). These findings were confirmed on upper gastrointestinal endoscopy which shows periampullary diverticulum and signs of diverticula erythema and inflammation and normal appearing ampulla of Vater. After confirming with endoscopy, the patient was kept nil by mouth for few days and put on medical treatment with intravenous metronidazole and imipenem and shows good results and cholangitis resolution as her fever subsided within 2-3 days and her blood count was returning to normal and liver enzyme was normalized. By clinical presentation and evolution Lemmel syndrome was diagnosed and conservative managed and she was discharged after 1 week with antacids and without any intervention. She had been well thereafter. When the patient visited the outpatient clinic for follow up her repeat liver enzymes shows normal reports and repeat endoscopy for follow up study shows normal mucosa in PAD. She remains clinically and endoscopically disease free after the last admission.

DISCUSSION

Duodenal diverticulum incidence is estimated between 1 to 27% in general population depending on the consulted series. It is usually founded incidentally. Diverticula of the gastrointestinal tract are out pouchings of all or part of the intestinal wall

Praveen S Padasali,
Vinayak Thakkannavar

Department Of Surgery, BIMS, Belagavi,
Karnataka- 590001, INDIA.

Correspondence

Dr. Praveen S Padasali

Maitri Galli, Jamkhandi, D-Bagalkot,
Karnataka-587301, INDIA.

Phone: +91-9880981480

Email: pravsp12@gmail.com

History

- Submission Date: 13-12-2017;
- Review completed: 24-01-2018;
- Accepted Date: 05-11-2018.

DOI : 10.5530/ogh.2018.7.2.25

Article Available online

<http://www.oghreports.org/v7/i2>

Copyright

© 2018 Phcog.Net. This is an open-access article distributed under the terms of the Creative Commons Attribution 4.0 International license.

Cite this article: Padasali PS, Thakkannavar V. A Unusual Case of Painless Obstructive Jaundice and Cholangitis: Lemmel's Syndrome- A Case Report. OGH Reports. 2018;7(2):106-8.

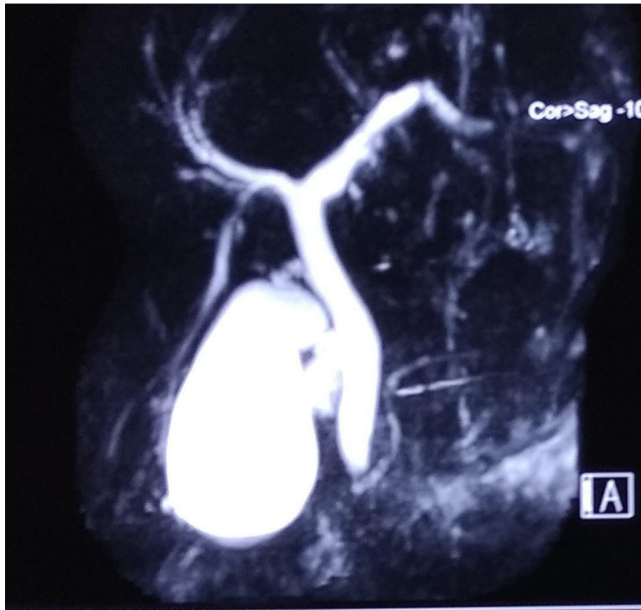


Figure 1: MRCP images showing CBD and Pancreatic duct with tapering end.

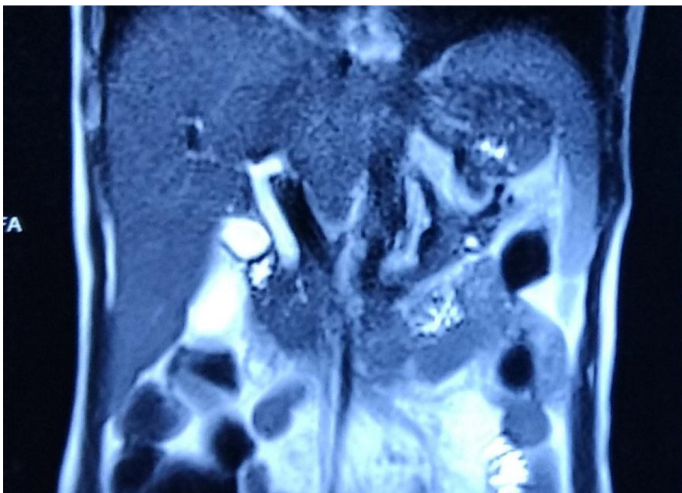


Figure 2: MRCP showing Distal CBD compressing with periamпуляр diverticulum.

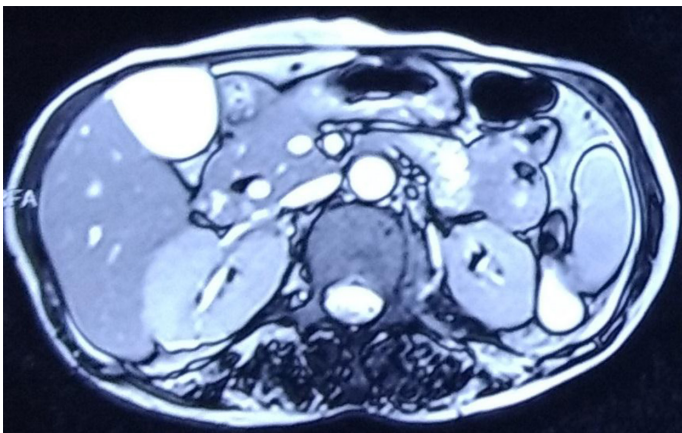


Figure 3: Distal CBD compressing BY Intraparenchymal periamпуляр diverticulum.

which can occur anywhere throughout the alimentary tract. The most common site of gastrointestinal diverticula is colon followed by duodenum, which was first described by Chomel in 1710.^[3] According to the anatomical classification after colangio-pancreatic magnetic resonance are divided in four types, with the juxtapapillar or periampullar being the most frequent in 75% of cases.^[4] Most PAD are asymptomatic but complications can occur in about 5% of cases and they include bleeding, perforation, diverticulitis, pancreatitis, choledocholithiasis, cholangitis, jaundice, enterolith or bezoar formation, intestinal obstruction, etc and less than 1% require surgical treatment.^[5] In the presented case the diagnosis was suspected only after the icterus and fever. Fortunately, although the radiological diagnosis and medical management indicated in this case and patient condition had good outcomes this time. The pathophysiology is explained by some different theories including diverticulitis or mechanical irritation of periampullar diverticula that may cause inflammation of the ampulla that would lead to fibrosis. Another theory is that diverticula itself may cause dysfunction of sphincter of Oddi by anatomical modifications of angles and sphincters, in fact distal common biliary duct or ampulla can be compressed mechanically leading to jaundice, sometimes intermittent and in other cases favoring the increase on incidence of choledocholithiasis by colonization and overgrowth of β -glucuronidase producing bacteria, which in turn lead to deconjugation of bilirubin glucuronides and results in precipitation of calcium bilirrubinate gallstones.^[6,7] The diagnosis usually is by direct visualization of duodenal diverticula by endoscopy and confirmed by CT scan images describing as thin-walled cavitory lesions situated on the medial wall of the duodenum 2nd portion that typically contain gas. If diagnostic dilemma cholangiopancreatic magnetic resonance to be done as it is gold standard. The preferred treatment and with the better results and reduced morbidity is the ERCP with sphincterotomy and endoprosthesis placement, with cannulation rates of 94.9% in some series and complications like bleeding or perforation in 7.8%.^[8,9] There is a consensus that elective surgical treatment of asymptomatic diverticulum is not justified but in case of require this approach the diverticulectomy or biliodigestive anastomosis would be the surgical options.^[5,6,9] However, PAD are sometimes filled with fluid and can frequently be mistaken for pancreatic pseudocyst, pancreatic abscess, cystic neoplasm in the pancreas head or even metastatic lymph node.^[10,11] Treatment is generally not recommended in asymptomatic patients or would be conservative management in pauci-symptomatic patients. Nevertheless, since most patients with Lemmel's syndrome present with symptoms related to biliary obstruction (i.e. jaundice, abdominal pain and cholangitis) as a result of extrinsic compression of CBD, some form of treatment is advocated

CONCLUSION

Lemmel's syndrome is a rare cause of obstructive jaundice that should be included in the differential diagnosis of biliary obstruction when PAD is present. Ignoring this possibility could lead to repetitive jaundice and in some cases cholangitis, with the high morbidity and mortality associated. Maintaining a high index of suspicion is required to establish an accurate diagnosis since it can mimic other cystic or solid lesions around the pancreas head. Symptomatic patient can be successfully managed endoscopically in many instances but recourse to surgical management would be necessary in selected cases.

REFERENCES

1. Lemmel G. Die Klinische Bedeutung der Duodenal Divertikel. Arch Verdauungskrht. 1934;46:59-70.
2. Lobo DN, Balfour TW, Iftikhar SY, Rowlands BJ. Periampullar diverticula and pancreaticobiliary disease. Br J Surg. 1999;86(5):588-97.
3. Wiesner W, Beglinger Ch, Oertli D, Steinbrich W. Juxtapapillary duodenal

- diverticula: MDCT findings in 1010 patients and proposal of a new classification. *JBR-BTR*. 2009;92(4):191-4.
4. Chomel JB. Report of a case of duodenal diverticulum containing gallstones. *Histoire Acad R Sci Paris*. 1710:48-50.
 5. Cabrerizo García JL, Zalba Etayo B Intermittent obstructive jaundice by Lemmel's síndrome. *Gastroenterol Hepatol*. 2010;08:152-3.
 6. Kang HS, Hyun JJ, Kim SY, Jung SW, Koo JS. *et al*. Lemmel's Syndrome, an Unusual Cause of Abdominal Pain and Jaundice by Impacted Intradiverticular Enterolith: Case Report. *J Korean Med Sci*. 2014;29(6):874-8.
 7. Skar V, Skar AG, Bratlie J, Osnes M. Beta-glucuronidase activity in the bile of gallstone patients both with and without duodenal diverticula. *Scand J Gastroenterol*. 1989;24(2):205-12.
 8. Rouet J, Gaujoux S, Ronot M, Palazzo M, Cauchy F, *et al*. Lemmel's syndrome as a rare cause of obstructive jaundice. *Clin Res Hepatol Gastroenterol*. 2012;36(6): 628-31.
 9. Lobo DN, Balfour TW ERCP for intradiverticular papilla: not the latest trick. *Gastrointest Endosc*. 1999;50(1):144.
 10. Macari M, Lazarus D, Israel G, Megibow A. Duodenal diverticula mimicking cystic neoplasms of the pancreas: CT and MR imaging findings in seven patients. *AJR Am J Roentgenol*. 2003;180(1):195-9.
 11. Kim SY, Kim JN, Kwon SO, Cha IH, Ryu SH, KimYS, Moon JS. A case of duodenal diverticulum mimicking a peripancreatic abscess. *Korean J Med*. 2013;84:249-53.

Cite this article: Padasali PS, Thakkannavar V. A Unusual Case of Painless Obstructive Jaundice and Cholangitis: Lemmel's Syndrome- A Case Report. *OGH Reports*. 2018;7(2):106-8.